




# CAVECTOMY FOLLOWING THROMBECTOMY FOR WILMS' TUMOUR WITH INTRACAVAL TUMOUR THROMBUS: A CASE REPORT AND LITERATURE REVIEW



Aiman Adi Sufian Chan<sup>1</sup>, Muhammad Azri Salleh<sup>1</sup>, Muhammad Luqman Nazmi<sup>1</sup>, Norhafiza Ab. Rahman<sup>2,3</sup>, Mohd Yusran Othman<sup>3</sup>, Zakaria Zahari<sup>3</sup>  
<sup>1</sup>Kulliyah of Medicine, International Islamic University Malaysia, Kuantan, Pahang, Malaysia  
<sup>2</sup>Department of Surgery, Kulliyah of Medicine, International Islamic University Malaysia, Kuantan, Pahang, Malaysia  
<sup>3</sup>Department of Paediatric Surgery, Hospital Tunku Azizah, Kuala Lumpur, Malaysia

## Introduction

Wilms' tumour is the commonest renal tumour in children. With a predisposition of forming tumour thrombus in blood vessels, tumour extension into renal veins and inferior vena cava (IVC) has been reported in up to 10% of cases. Neoadjuvant chemotherapy has been shown to promote intracaval tumour regression, however in cases of persistent thrombus, thrombectomy is required along with radical nephrectomy via cavotomy. We shared a rare complication of thrombectomy which required a cavectomy.

## Case Summary

We are reporting a case of right Wilms' tumour in a 7 year-old girl with tumour extension into IVC (Figure 1). After three courses of neoadjuvant chemotherapy, she developed duodenal obstruction caused by the tumour and the repeated imaging showed non-regression of the intracaval tumour thrombus (Figure 2). She underwent right radical nephrectomy with thrombectomy via cavotomy. However, ultrasound assessment after the surgery revealed that the IVC was filled with blood clots which persisted even after administration of anticoagulant (Figure 3). With the concern of pulmonary embolism, she was subjected to a second surgery. Intraoperatively, the IVC was found completely blocked at the level of intrahepatic IVC, thus decision was made for cavectomy without reconstruction (Figure 4). To date, up until 1.5 years after surgery, she remains well.

## Discussion

In cases of Wilms' tumour as in our case, the tumour thrombus may extend into the IVC and right atrium<sup>1,3</sup>. The intravascular extension should be detected as early as possible by modalities such as ultrasound with Doppler and computed tomography since it may lead to complications from venous outflow obstruction and risk of embolism<sup>1,4</sup>. The presence of tumour thrombus may also complicate the management strategies. Chemotherapy can reduce the size of thrombus because of its chemosensitivity, however in some cases like our patient, it may not cause regression and persisted. Therefore, surgical intervention is indicated depending on the level of the tumour thrombus<sup>2,3,4</sup>. Cavectomy is one of the treatment of choice especially when the thrombus firmly adhered to the caval wall<sup>3</sup>. However, the long term outcome of cavectomy without reconstruction for children is not widely known with only a few evidence available in the literature. We summarized the case reports of similar cases like ours in Table 1.

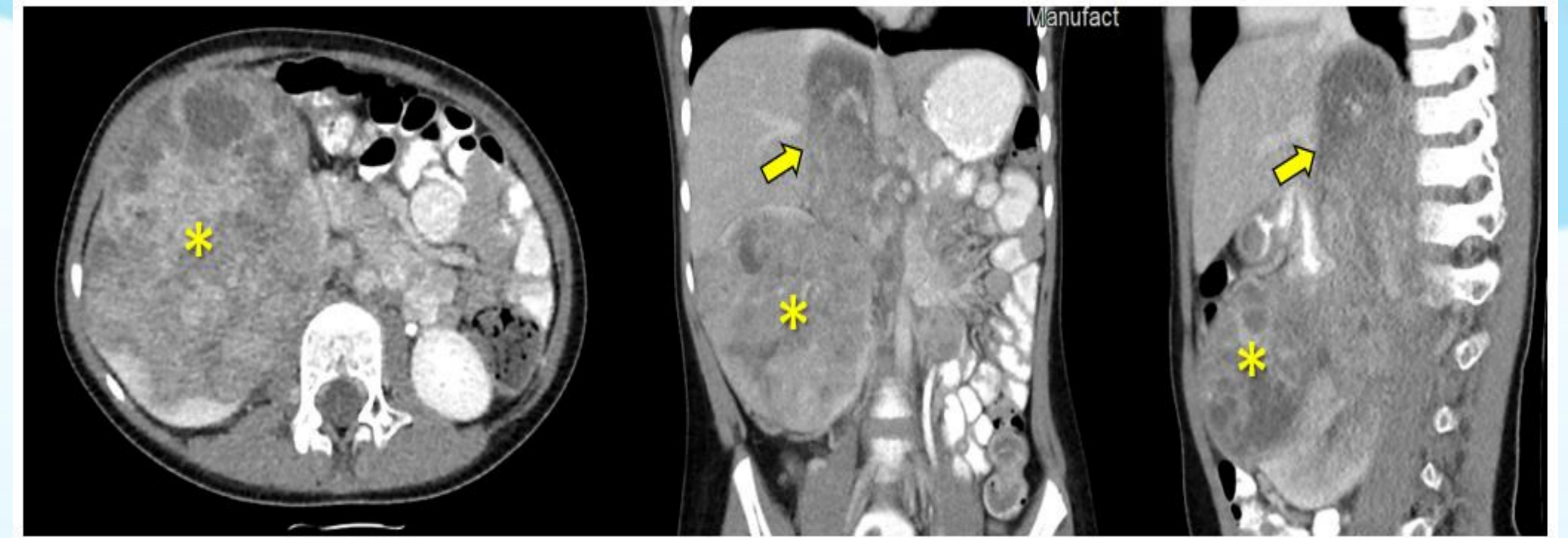


Figure 1: CT images at diagnosis showing huge tumour arising from the right kidney (asterisk) with intracaval tumour thrombus up to the suprahepatic level (arrow)

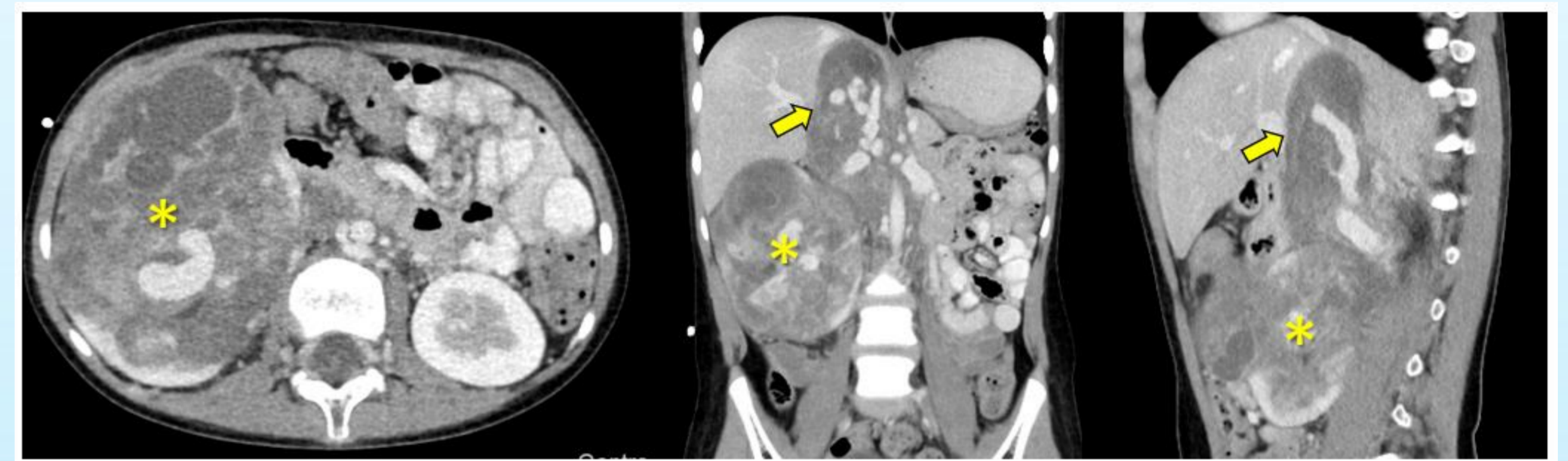


Figure 2: CT images after neoadjuvant chemotherapy showed no significant changes of primary tumour size (asterisk) and the non-resolution of the intracaval tumour thrombus (arrow)

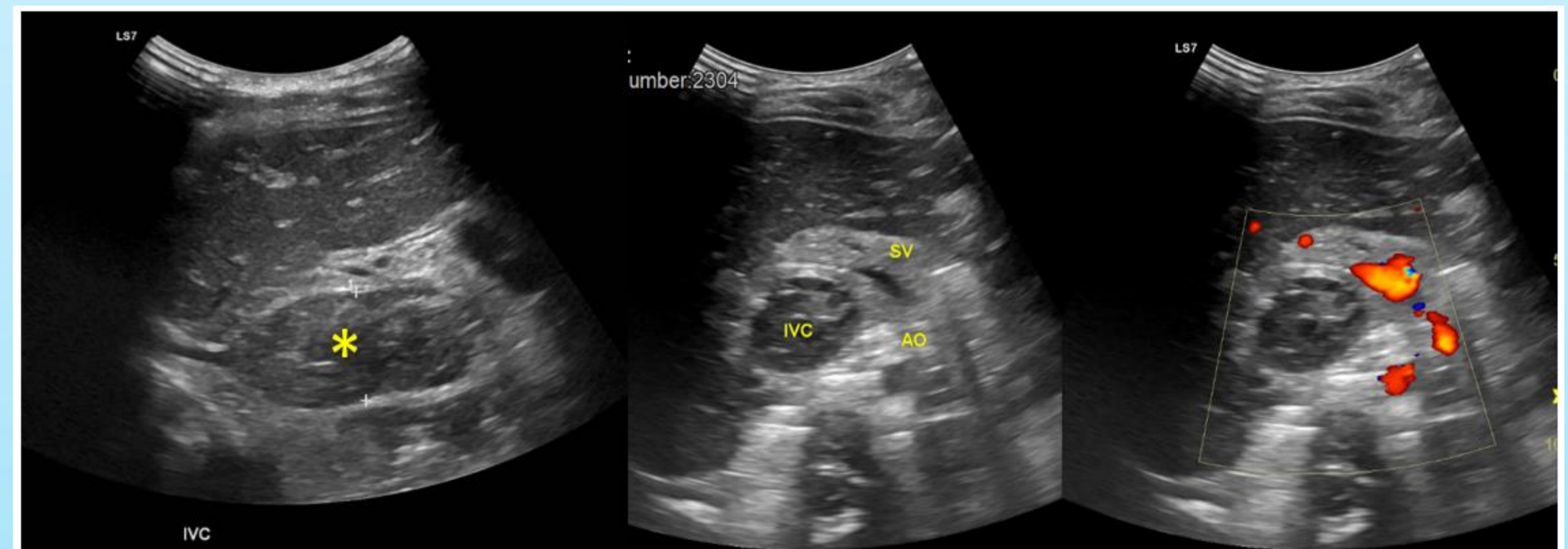


Figure 3: Ultrasound images after right nephrectomy revealed enlarged IVC with filling defect within suggestive of thrombosis (asterisk) with poor colour Doppler

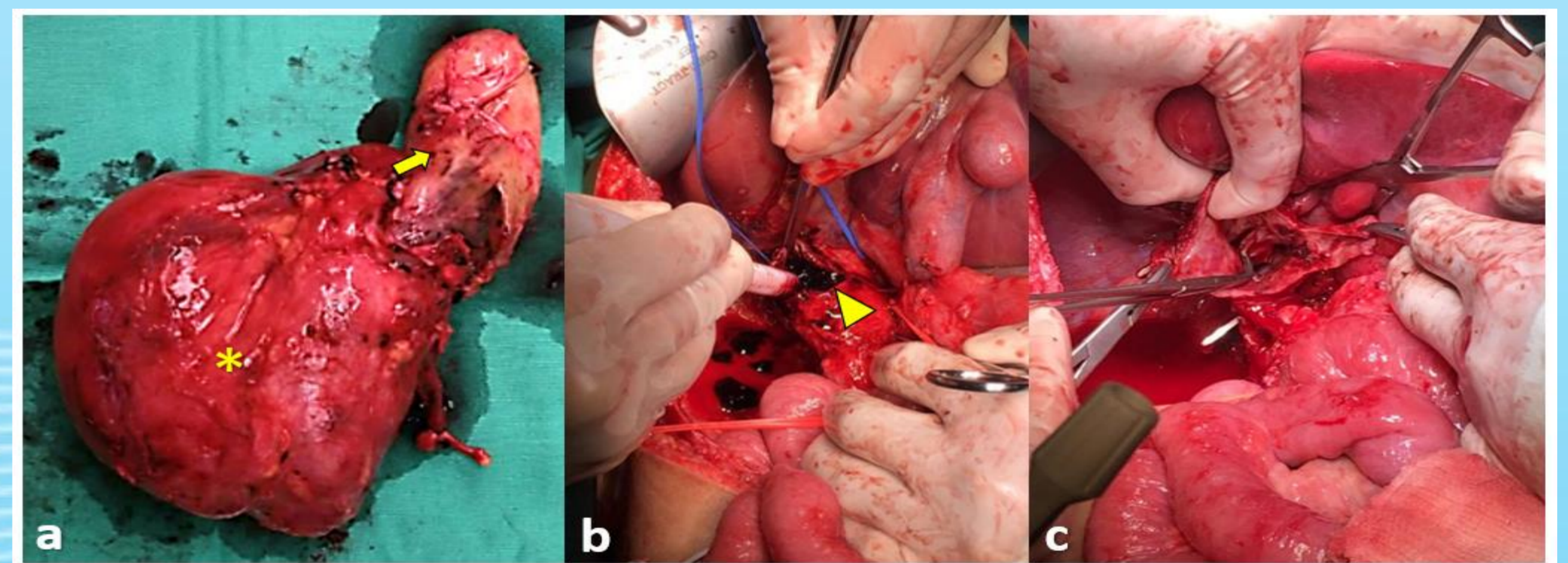


Figure 4: Resected right renal tumour (asterisk) with its tumour thrombus (arrow) at first surgery (a). At the following surgery, upon cavotomy (arrowhead) the IVC was noted to be filled up with blood clots (b) and poor back flow of blood from distal IVC (c), thus decision was made for cavectomy without reconstruction

No	Author	Age	Sex	Stage	Neo-adjuvant	Site	Level of thrombus at diagnosis	Level of thrombus after chemo	Timing of cavectomy	Indication of cavectomy	Postoperative Outcome	Survival Outcome
1	Dale et al. (1995)	8y	F	I	None	Right	NA	Intrahepatic	4 years	NA	Uneventful	NED at 18m
2		25mo	F	II	Yes	Right	Intracardiac	Intrahepatic	En-bloc	Adherence	Uneventful	NED at 9y
3	Ceccanti et al. (2020)	8.5y	M	V	Yes	Bilateral	Intrahepatic	NA	En-bloc	Adherence	Uneventful	NED at 30m
4		5y	F	IV	Yes	Right	Intracardiac	Intracardiac	En-bloc	NA	Uneventful	NED at 25m
5	Renaud et al. (2001)	4y	F	IV	Yes	Left	NA	Intrahepatic	En-bloc	Adherence	Uneventful	NED at 7y
6		4y	F	III	Yes	Right	NA	NA	En-bloc	Adherence	Uneventful	NED at 11y
7	Ribeiro et al. (2006)	3y	F	?	Yes	Right	Intrahepatic	Intrahepatic	En-bloc	Adherence	Uneventful	NED at 1.5y
8		7y	F	?	Yes	Right	Intracardiac	Intracardiac	En-bloc	Adherence	Uneventful	NED at 1y
9	Abdullah et al. (2013)	NA	NA	IV	Yes	Right	Intracardiac	Intracardiac	NS	Adherence	Uneventful	Died of relapse
10		NA	NA	IV	Yes	NA	Intracardiac	Intracardiac	NS	Adherence	NA	Died peri-operatively
11		NA	NA	III	Yes	Right	Intracardiac	Intracardiac	NS	Adherence	Uneventful	NED at 18m

NA: Not available, NED: No evidence of disease, NS: Non-Specified

Table 1: Literature review on cases of cavectomy in children with Wilms' Tumour

## Conclusion

Surgical excision of Wilms' tumour with intravascular invasion is challenging. IVC wall injury following thrombectomy may end up with cavectomy. Cavectomy without reconstruction in children is generally safe with no major sequelae has been reported.

## References

- Abdullah, Y., Karpelowsky, J., Davidson, A., Thomas, J., Brooks, A., Hewitson, J., Numanoglu, A., Cox, S., & Millar, A. J. (2013). Management of nine cases of Wilms' tumour with intracardiac extension - a single centre experience. *Journal of pediatric surgery*, 48(2), 394-399. <https://doi.org/10.1016/j.jpedsurg.2012.11.024>
- Bhatnagar S. (2009). Management of Wilms' tumor: NWTS vs SIOP. *Journal of Indian Association of Pediatric Surgeons*, 14(1), 6-14. <https://doi.org/10.4103/0971-9261.54811>
- Ribeiro, R. C., Schettini, S. T., Abib, S. D. C. V., da Fonseca, J. H. P., Cypriano, M., & da Silva, N. S. (2006). Cavectomy for the treatment of Wilms tumor with vascular extension. *The Journal of urology*, 176(1), 279-284.
- Szavay, P., Luthle, T., Semler, O., Graf, N., & Fuchs, J. (2004). Surgery of cavoatrial tumor thrombus in nephroblastoma: a report of the SIOP/GPOH study. *Pediatric blood & cancer*, 43(1), 40-45. <https://doi.org/10.1002/pbc.20056>
- Ceccanti, S., Büyükkönel, C., Emre, Ş., Masselli, G., Schiavetti, A., & Cozzi, D. A. (2021). Resection of Inferior Vena Cava Without Reconstruction for Intravascular Intrusion of Wilms Tumor. *Urology*, 149, e29-e33.
- Renaud, E. J., Liu, D., Pipe, S. W., Rubin, M. A., & Teitelbaum, D. H. (2001). Inferior vena cavectomy for nonexcisable Wilms' tumor thrombus. *Journal of pediatric surgery*, 36(3), 526-529. <https://doi.org/10.1053/jpsu.2001.21626>
- Dale PS, Webb HW, Wilkinson AH Jr. Resection of the inferior vena cava for recurrent Wilms' tumor. *J Pediatr Surg*. 1995 Jan;30(1):121-2. doi: 10.1016/0022-3468(95)90628-2. PMID: 7722816

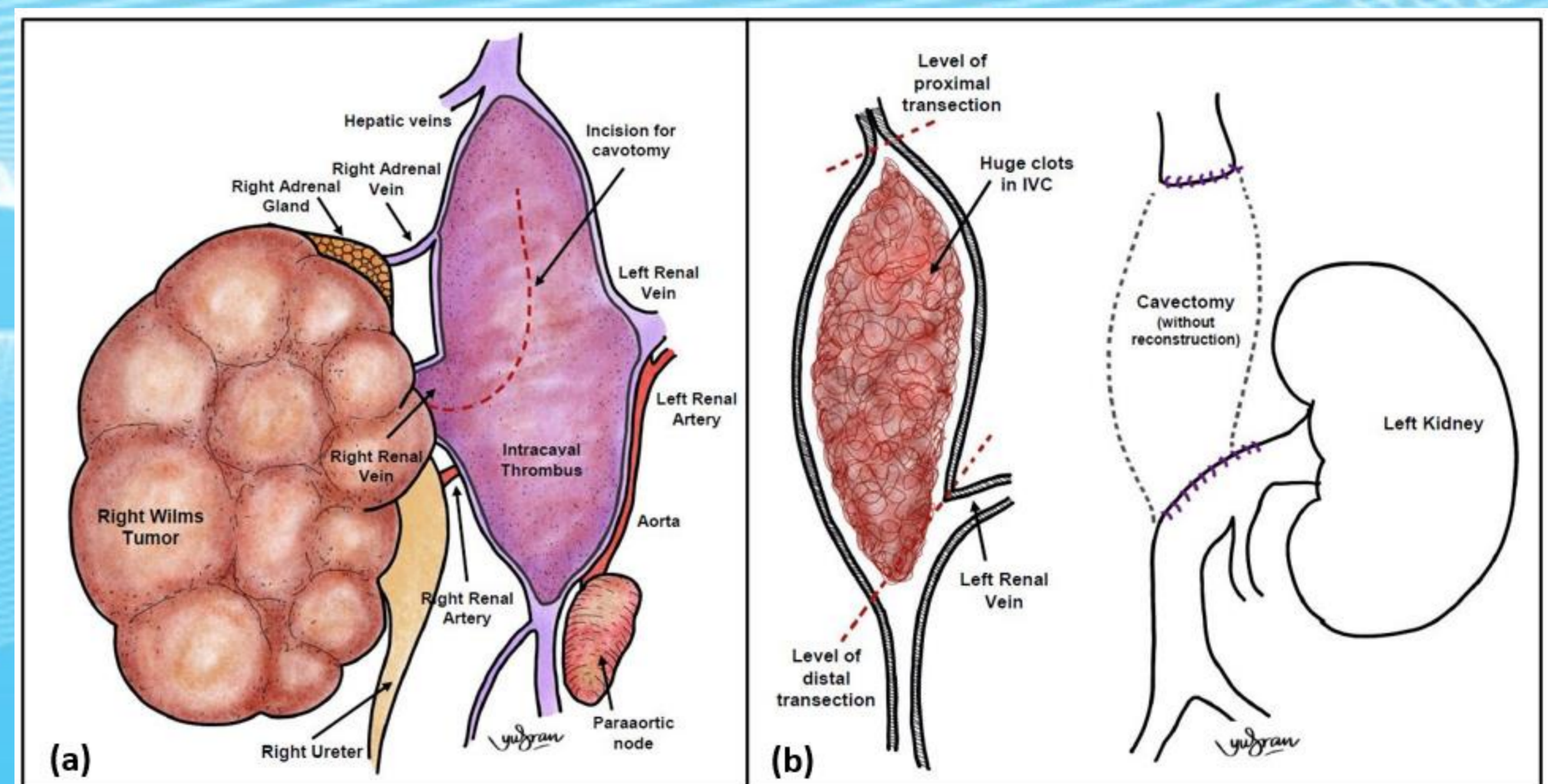


Figure 5: Operative illustration during the first surgery demonstrate the huge intracaval tumour thrombus (a) and then it was filled by a huge clot (b) during the second surgery, thus cavectomy without reconstruction was performed.

